

# Free Functioning Gracilis Transfer for Traumatic Brachial Plexus Injuries in Children

Harvey Chim, MBBS, Michelle F. Kircher, BS, Robert J. Spinner, MD,  
Allen T. Bishop, MD, Alexander Y. Shin, MD

**Purpose** To report our technique and experience with use of free functioning muscle transfer (FFMT) in reconstruction of traumatic brachial plexus injuries (BPIs) in children as well as its complications and outcomes.

**Methods** Twelve patients with complete BPI underwent FFMT for reconstruction between 2000 and 2012. Eight had single-stage gracilis transfer for restoration of elbow flexion, and 4 children had double free gracilis muscle transfer for restoration of elbow flexion and prehension. Mean duration of follow-up was 27 months (range, 14–55 mo).

**Results** Eleven out of 12 patients achieved at least M3 elbow flexion, with 8 patients achieving M4 or greater elbow flexion. Eight of 12 patients had nerve transfers to the musculocutaneous nerve. Mean active elbow arc of motion was 79° (range, 30°–130°). Two patients aged 8 and 11 years with open growth plates developed elbow joint contractures, which limited range of motion, but they recovered M4 and M5 elbow flexion strength.

**Conclusions** FFMTs can result in good outcomes following reconstruction for traumatic BPI. The use of FFMT should be carefully considered in children prior to skeletal maturity because of the risk of the development of an elbow flexion contracture. (*J Hand Surg Am.* 2014; 39(10):1959–1966. Copyright © 2014 by the American Society for Surgery of the Hand. All rights reserved.)

**Type of study/level of evidence** Therapeutic IV.

**Key words** Brachial plexus injury, gracilis transfer.

FOR PATIENTS WITH COMPLETE traumatic brachial plexus injuries (BPIs), limited options are available for reconstruction. The paucity of available donor nerves for reconstruction of shoulder, elbow, and hand function, as well as the inability to reliably reconstruct distal motor nerves, makes free functioning muscle transfer (FFMT) an attractive option

for restoration of upper extremity function, especially prehension.<sup>1</sup> In children, traumatic BPIs are relatively rare,<sup>2</sup> and reports on the treatment of such injuries is limited. Sixty-three percent to 73% are preganglionic lesions.<sup>2,3</sup>

Whereas FFMT has been widely used in adults for reconstruction of elbow function<sup>4</sup> and prehension<sup>5,6</sup> and in children with late sequelae of obstetric brachial plexus palsy,<sup>7,8</sup> we found only 3 instances of using FFMT for reconstruction in children following traumatic brachial plexus palsy.<sup>9</sup> The condition constitutes 1% of all brachial plexus lesions reported by Boome.<sup>10</sup>

In children, considerations for the use of FFMT include the presence of open growth plates and potential growth that may affect long-term outcomes. The most active physes in the upper extremity are the proximal humerus (which results in 80% of longitudinal

From the Department of Orthopedic Surgery, Division of Hand Surgery, and the Department of Neurosurgery, Mayo Clinic, Rochester, MN.

Received for publication November 14, 2013; accepted in revised form June 17, 2014.

No benefits in any form have been received or will be received related directly or indirectly to the subject of this article.

**Corresponding author:** Alexander Y. Shin, MD, Department of Orthopedic Surgery, Division of Hand Surgery, Mayo Clinic, 200 1st St. South West, Rochester, MN 55905; e-mail: [shin.alexander@mayo.edu](mailto:shin.alexander@mayo.edu).

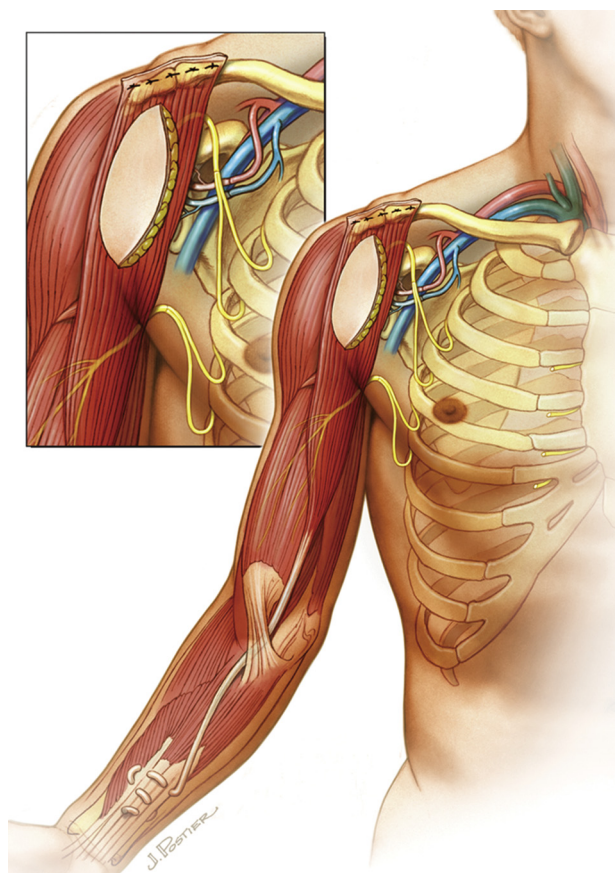
0363-5023/14/3910-0010\$36.00/0  
<http://dx.doi.org/10.1016/j.jhssa.2014.06.020>

growth of the humerus<sup>11</sup>) and the distal radius. The humerus increases in length yearly by approximately 1.3 cm/y in boys and 1.2 cm/y in girls from age 7 until skeletal maturity, while the length of the radius increases annually approximately 1.0 cm/y in boys and 0.9 cm/y in girls.<sup>12</sup> Although there is no evidence in the literature about growth rates of the gracilis muscle, discrepant growth between the transferred muscle and the rest of the upper extremity might result in joint contracture. Unfortunately, the extent and type of the injury in many patients does not allow other reconstructive options that can approach outcomes potentially achievable with FFMT. In this article, we report our technique and experience with use of FFMT in reconstruction of traumatic BPIs in children and its complications and clinical results.

## MATERIALS AND METHODS

### Patients

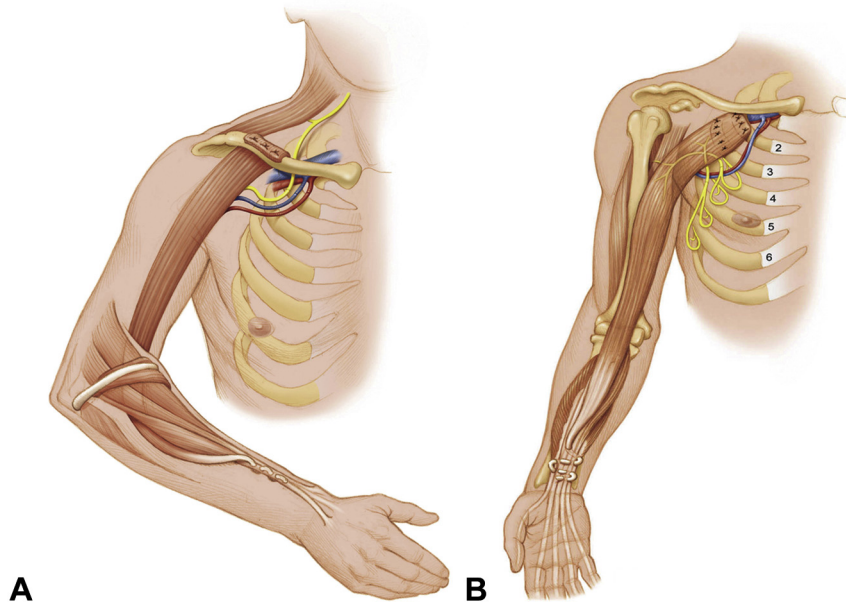
Following review by our institutional review board, a retrospective chart review of all patients treated with FFMT for traumatic BPIs between 2000 and 2012 was performed. Inclusion criteria comprised all patients 17 years of age or younger at the time of surgery who had FFMT for traumatic BPIs. All FFMT used the gracilis muscle for elbow flexion. There were 16 patients who met inclusion criteria. Of these, 4 patients (3 single FFMT, 1 double FFMT) had follow-up of 7 months or less (owing to inability to return to our center secondary to financial or distance issues); these were excluded from the study, leaving 12 patients with at least 14 months of postoperative follow-up who constituted the cohort for this study. All patients were evaluated clinically prior to surgery by the senior authors (A.Y.S., R.J.S., A.T.B.) and had an electromyogram (EMG) together with computed tomography and/or magnetic resonance imaging myelogram to define the extent and level of the injury including the presence of a preganglionic injury. Reconstructive options were discussed with the families and included use of nerve transfers, nerve grafts, free functioning gracilis transfers, or a combination thereof. Discussion includes consideration of performing either a single gracilis transfer to restore elbow flexion and finger flexion (14) (Fig. 1) or a double gracilis transfer to restore elbow flexion and prehension<sup>5,6</sup> (Fig. 2). Families and patients expressed their desires for reconstruction, and a surgical plan was formulated understanding that intraoperative findings and intraoperative electrodiagnostic studies would dictate the ultimate surgical plan. Final decision for reconstruction with FFMT and



**FIGURE 1:** Single gracilis transfer for restoration of elbow flexion and finger flexion. Inset shows microanastomoses from thoracoacromial trunk to gracilis vessels and coaptation of intercostal motor nerves 3 and 4 to nerve to obturator branch of the gracilis, and intercostal motor nerves 5 and 6 to the biceps motor branch of the musculocutaneous nerve. (By permission of Mayo Foundation for Medical Education and Research. All rights reserved.)

adjunctive nerve transfers was performed at the time of surgery, after surgical exploration of the brachial plexus and intraoperative electrodiagnostic studies.

Our indications for reconstruction with FFMT were patients who lacked suitable nerve donors for nerve grafting or nerve transfers. The use of FFMT was planned before surgery after review of electrodiagnostic and imaging studies and confirmed during surgery with electrodiagnostic studies. In general, patients with panplexus injuries were considered for FFMT after discussion with patients and families about the complexity and risk of surgery and the need for strict adherence to postoperative rehabilitation protocols. Patients were candidates for a single FFMT surgery regardless of time from injury and for a double FFMT (to restore elbow flexion and prehension) only if they were within 6 months from injury. Contraindications for FFMT included patients and



**FIGURE 2:** Double gracilis transfer for restoration of elbow flexion and prehension. **A** Stage I of the double free gracilis transfer aims to restore elbow flexion and wrist or finger extension. **B** Stage II of the double free gracilis transfer aims to restore finger flexion. (By permission of Mayo Foundation for Medical Education and Research, All rights reserved.)

families who were not able or not willing to adhere to postoperative rehabilitation protocols and those with previously damaged or nonviable gracilis muscles or donor vessels. Contraindication to double FFMT included lack of sufficient donors to perform nerve transfer to reinnervate the triceps.

#### Outcome measures

Patients were evaluated after surgery to assess recovery of muscle strength with the modified grading system of the British Medical Research Council<sup>13</sup> and active range of motion at the shoulder and elbow joints.

#### Surgical technique

A transverse incision around 2.5 cm cephalad to the clavicle with a cephalic extension along the lateral border of the sternocleidomastoid muscle (if needed) is used to expose the supraclavicular plexus, and an incision along the deltopectoral groove is used for exposure of the infraclavicular plexus. If the C5 root is found and not avulsed from the spinal cord, the root may be used to reconstruct the axillary and suprascapular nerves with an intervening nerve graft, provided that intraoperative electrodiagnostic studies confirm viability. Viability of the nerve roots is determined using intraoperative monitoring to determine presence of somatosensory evoked potentials and motor evoked potentials.

Our technique for harvest and transfer of the gracilis as an FFMT has been previously described.<sup>14</sup> The intercostal nerves (ICN) or spinal accessory nerve (SAN) are the donor nerves of choice for reinnervation of the transferred gracilis muscle related to whether or not prehension is to be reconstructed. We have modified<sup>13</sup> the technique described by Doi et al.<sup>5-7,9</sup> In the first stage, the gracilis is secured distally to wrist extensors instead of finger extensors to augment finger flexion through a tenodesis effect. In addition, we use the flexor carpi ulnaris to create a pulley in the proximal forearm to reduce bowstringing of the gracilis across the elbow. The single gracilis transfer is a reliable technique to restore elbow flexion in our experience,<sup>4</sup> with 79% of patients achieving at least M4 elbow flexion strength. We offer this option to patients who may not wish to undergo the prolonged process of double gracilis transfer and to those patients who present too late to reinnervate the triceps or who do not have sufficient donor nerves to transfer to the nerve to the triceps to restore elbow extension.

Adjunctive nerve transfers are performed during the same surgery, with final decision of donor nerves and nerve transfers based on intraoperative findings. Transfer of the SAN or ICN is performed to the nerve to the triceps to restore elbow extension, especially when prehension is desired for an FFMT that crosses the elbow joint anteriorly. Transfer of the ICN to the biceps branch or the formal musculocutaneous nerve (MCN) may be performed to augment elbow flexion.

**TABLE 1. Demographic Data of Patients**

| n           | Sex | Gender | Mechanism of Injury | Extent of Injury | Avulsed Nerve Roots | Delay From Injury to Surgery (mo) | Last Follow-Up (mo) |
|-------------|-----|--------|---------------------|------------------|---------------------|-----------------------------------|---------------------|
| <b>SFMT</b> |     |        |                     |                  |                     |                                   |                     |
| 3           | 14  | Male   | ATV                 | C5–8             | C5–8                | 3                                 | 30                  |
| 4           | 16  | Male   | Motor vehicle       | C5–T1 (complete) | C5–T1               | 5                                 | 25                  |
| 5           | 11  | Male   | Motor vehicle       | C5–T1 (complete) | C7–T1               | 2                                 | 55                  |
| 6           | 6   | Male   | Motor vehicle       | C5–T1 (complete) | C7–T1               | 6                                 | 32                  |
| 7           | 17  | Male   | Football            | C5–T1 (complete) | C5–T1               | 3                                 | 22                  |
| 9           | 16  | Male   | Motor vehicle       | C6–T1            | C6–T1               | 6                                 | 25                  |
| 11          | 13  | Male   | PED vs vehicle      | C5–T1 (complete) | C7–T1               | 4                                 | 14                  |
| 12          | 17  | Male   | Motorcycle          | C5–T1 (complete) | C6–T1               | 5                                 | 19                  |
| <b>DFMT</b> |     |        |                     |                  |                     |                                   |                     |
| 1           | 15  | Female | Motor vehicle       | C5–T1 (complete) | C6–7                | 3                                 | 36                  |
| 2           | 15  | Male   | Car vs bicycle      | C5–T1 (complete) | C5–T1               | 3                                 | 28                  |
| 8           | 8   | Male   | Motor vehicle       | C5–T1 (complete) | C5–T1               | 5                                 | 27                  |
| 10          | 17  | Male   | Football            | C6–T1 (complete) | C7–T1               | 5                                 | 14                  |

ATV, all-terrain vehicle accident; n, patient number; Ped, pedestrian.

After surgery, patients are observed in the intensive care unit where they undergo hourly flap monitoring. Anticoagulation regimen consists of aspirin 325 mg orally daily and dipyridamole (Persantine) 25 mg orally 3 times daily. Patients are typically discharged by the fifth postoperative day and started on range of motion rehabilitation after 3 weeks of immobilization. The shoulder is immobilized in 30° of abduction and flexion and 60° of internal rotation with the elbow in 100° of flexion, while the wrist is in neutral and fingers in forced flexion or extension depending on the type of reconstruction. Secondary procedures such as tendon transfers, wrist arthrodesis, and pulley reconstruction are performed at least one year later<sup>15</sup> but are often delayed in children until skeletal maturity because these procedures may interfere with skeletal growth.

## RESULTS

Patient data are summarized in Table 1. The average age of patients was 13.8 ± 3.6 years. Eleven out of 12 patients were boys, and the mechanism of injury was predominantly motor vehicle accidents. All patients had partial (n = 8) or complete (n = 4) (C5–T1) root avulsion injuries. Mean follow-up was 27 months (range, 14–55 mo). Double free muscle transfer (DFMT) was performed in 4 patients, and single gracilis transfer was performed in 8 patients. All patients had surgery within 6 months of injury. The

SAN was used as the donor nerve for the first stage of all DFMTs, and ICNs were used as donor nerves for second-stage DFMTs and all single gracilis transfers.

Adjunctive nerve transfers were performed in all patients (Table 2). Eight out of 12 patients had nerve transfers to the MCN, which might have confounded analysis of outcomes. Nevertheless, it is our practice to optimize outcomes for patients through all available means. Nerve transfer to the triceps motor branch was performed in all patients except one (patient 11) in whom the SAN was not available as a donor and C5 and C6 nerve roots were also deemed to be nonviable during surgery with somatosensory and motor evoked potentials. Hence, the decision was made to focus reconstructive efforts on elbow flexion and hand sensibility through ICN transfer to the ulnar nerve, with subsequent tendon transfers to stabilize the shoulder. Other nerve transfers to the MCN, lateral cord to median nerve and axillary/suprascapular nerve were performed based on availability of donor nerves and discussion of reconstructive priorities with the patient and family.

Patient results are summarized in Table 3. Eight out of 12 patients achieved M4 or better elbow flexion. Three other patients achieved M3 elbow flexion. Thus, 11 of 12 patients achieved M3 or better. Mean arc of motion of the elbow (from maximal extension to flexion) was 79° (range of mean arc of motion, 30°–130°). Two patients developed greater than 30°



**TABLE 2. Ancillary Procedures Performed**

| n   | Procedure Performed | Donor Nerves |         | Additional Procedures Performed |                              |                                 |                     |   |
|-----|---------------------|--------------|---------|---------------------------------|------------------------------|---------------------------------|---------------------|---|
|     |                     | Stage 1      | Stage 2 | Triceps NT                      | MCN NT                       | Lateral Cord to Median Nerve NT | Axillary and SSN NT | Tertiary Procedures   |
| 3   | SFMT                | ICN 3,4      |         | Yes (SAN)                       | Yes (ICN 5,6)                | No                              | Yes (C5)            | Tendon transfers (PL to EPL; FDS3 to EDC2–5; PT to ECRB)                                    |
| 4   | SFMT                | ICN 2,3      |         | Yes (CN XI)                     | Yes (ICN 4–6) (to biceps br) | No                              | No                  | Total wrist arthrodesis   |
| 5   | SFMT                | ICN 3,4      |         | Yes (SAN)                       | Yes (ICN 5,6)                | No                              | Yes (C5)            | Tenolysis and lengthening of biceps tendon, tendon transfers                                |
| 6*  | SFMT                | ICN 3,4      |         | Yes (SAN)                       | Yes (ICN 5,6)                | Yes (ICN 4–6)                   | Yes (C5)            | Pulley reconstruction   |
| 7   | SFMT                | ICN 3,4      |         | Yes (SAN)                       | Yes (ICN 5,6)                | Yes (ICN 3–6)                   | Yes (CC7)           | Total wrist arthrodesis, thumb CMC/IP joint arthrodesis                                     |
| 9   | SFMT                | ICN 3,4      |         | Yes (SAN)                       | No                           | No                              | No                  |   |
| 11  | SFMT                | ICN 2,3      |         | No                              | Yes (ICN 4–6)                | No                              | No                  | Shoulder tendon transfers   |
| 12† | SFMT                | ICN 3,4      |         | Yes (SAN)                       | Yes (ICN 5,6 to biceps br)   | Yes (ICN 4–6)                   | No                  | Total wrist arthrodesis   |
| 1   | DFMT                | SAN          | ICN 5,6 | Yes (ICN 3,4)                   | No                           | Yes (ICN 4–6)                   | No                  | Fractional lengthening flexor tendons, transfer of stage II gracilis to biceps tendon stump |
| 2‡  | DFMT                | SAN          | ICN 3,4 | Yes (ICN 5,6)                   | Yes (phrenic to biceps br)   | Yes (ICN 3,4)                   | Yes (CC7)           | Pulley reconstruction   |
| 8†† | DFMT                | SAN          | ICN 3,4 | Yes (ICN 5,6)                   | No                           | Yes (cable graft)               | Yes (CC7)           | Thumb IP joint arthrodesis  |
| 10  | DFMT                | SAN          | ICN 2–4 | Yes (ICN 5,6)                   | No                           | Yes (3–6)                       | No                  |   |

CC7, contralateral C7; CMC, carpometacarpal joint; ECRB, extensor carpi radialis brevis; EDC, extensor digitorum communis; EPL, extensor pollicis longus; FDS, flexor digitorum superficialis; IP, interphalangeal; n, patient number; NT, nerve transfer; PL, palmaris longus; PT, pronator teres; SSN, suprascapular nerve.

\*Patient 6 missing excision of skin paddle in tertiary procedures.

†Patient 12 missing thumb CMC/IP joint fusion in tertiary procedures.

‡Patient 2 missing thumb IP joint arthrodesis under tertiary procedures.

††Patient 8 had no tertiary procedures done.

elbow flexion contractures, but they recovered M4 and M5- elbow flexion strength. Data on elbow extension were available in 10 patients. Of these, 2 had M4- or greater elbow extension strength. The 2 patients with elbow flexion contracture had elbow extension strengths of M1 and M2. Of the 6 patients who underwent nerve transfers to the axillary nerve and suprascapular nerve, shoulder abduction strength ranged from M0 to M3. Data on mean arc of shoulder abduction, with corresponding range of motion, were available in 7 patients, with a mean of 27° (range, 0°–90°). Data on MRC grading of finger flexion were available in 8 patients, with 2 patients achieving M4 or

greater. There were no major neuropathic pain issues. When looking at the DFMT cohort only (n = 4), 2 out of 4 patients achieved M4 or better elbow flexion strength, whereas all patients achieved M3 strength or better. In the single free muscle transfer (SFMT) cohort only (n = 8), 6 out of 8 patients achieved M4 or better elbow flexion, with 7 patients achieving M3 or better.

Postoperative EMG was performed in 10 out of 12 patients. Details are shown in Table 4. The EMG showed reinnervation of the gracilis muscle in all patients and also reinnervation of the biceps muscle where a nerve transfer was performed to the branch to biceps or to the MCN.

**TABLE 3. Patient Outcomes**

| n           | Shoulder Abduction    |   | Elbow Function      |                       | Finger Function         |                     | Complications of Surgery                              |
|-------------|-----------------------|---|---------------------|-----------------------|-------------------------|---------------------|---|
|             | Abduction (MRC Grade) | Mean Active Abduction Arc of Motion (°) | Flexion (MRC Grade) | Extension (MRC Grade) | Total Active Motion (°) | Flexion (MRC Grade) |   |
| <b>SFMT</b> |                       |   |                     |                       |                         |                     |   |
| 3           | 2+                    | 30                                      | 4                   | 2                     | 100                     | 5                   | None  |
| 4           | 3–                    | 20                                      | 3–                  | 3–                    | 30                      | NA                  | None  |
| 5           | 3                     | NA                                      | 4                   | 2                     | 90                      | NA                  | Elbow joint contracture 45°                           |
| 6           | 0                     | 0                                       | 4+                  | 4+                    | 130                     | 2                   | None  |
| 7           | 2                     | 20                                      | 4–                  | 4–                    | 100                     | 2                   | Wound dehiscence right shoulder, thigh donor seroma   |
| 9           | 4                     | 90                                      | 5–                  | 2                     | 90                      | 0                   | None  |
| 11          | 3                     | 30                                      | 4                   | NA                    | 90                      | NA                  | Postoperative fall causing humerus fracture           |
| 12          | 0                     | 0                                       | 4–                  | 2                     | 100                     | 0                   | None  |
| <b>DFMT</b> |                       |   |                     |                       |                         |                     |   |
| 1           | 0                     | NA                                      | 3                   | NA                    | 40                      | 0                   | Stage II arterial thrombosis and loss of 40% gracilis |
| 2           | 1                     | NA                                      | 4                   | 2                     | 60                      | 4                   | None  |
| 8           | 1                     | NA                                      | 5–                  | 1                     | 50                      | NA                  | Stage II flap failure, elbow flexion contracture 80°  |
| 10          | 0                     | NA                                      | 3                   | 2                     | 70                      | 2                   | None  |

NA, not available.

Five patients developed complications following surgery. One patient had complete loss of the stage II gracilis for DFMT and also subsequently developed an 80° elbow flexion contracture. Another patient had an arterial thrombosis following stage II DFMT that required re-exploration and subsequently lost around 40% of the gracilis after debridement. One other patient developed an elbow contracture. Both patients with elbow joint contractures were among the youngest in our series, aged 11 and 8 years at the time of surgery, at the time of a critical period of growth of the skeleton of the upper extremity.

## DISCUSSION

Treatment of pediatric traumatic BPIs is controversial owing to the scarcity of reports.<sup>2,3,9,10,17,18</sup> We divide our approach to children with traumatic BPIs into 3 groups based on age. In children younger than 4 years, management is focused on restoring and maximizing hand function, similar to patients with obstetric BPIs. Subsequent priorities include restoration of elbow and shoulder function. In children older than 12 years, our approach is similar to that in adult patients. For these patients, the priorities for restoring function in order of importance are elbow flexion, shoulder abduction, and/or stability, wrist

extension and finger flexion, wrist flexion and finger extension, hand sensibility, and intrinsic function. This approach relies on maximizing function while prioritizing movements that have the least distance for nerves to regenerate to target muscles.

For children between 4 and 12 years old, in the most active phases of growth, there is sparse literature to guide management. However, nerve transfers have been used to restore elbow flexion and shoulder abduction owing to a high incidence of root avulsions.<sup>17,18</sup> Donor nerves that do not work as well in adults, for example, contralateral C7, may result in better outcomes in children owing to their enhanced regenerative capacity; however, minimal data are available to determine applicability. With pan-plexus injuries, our approach focuses on restoring elbow flexion, then shoulder abduction/external rotation. If exploration of the supraclavicular plexus reveals viable nerve roots/stumps, nerve grafts are used to reinnervate the axillary and suprascapular nerves for shoulder function. If additional roots are available, nerve grafts are used to target elbow flexion via the MCN or the branch to biceps. Through both the FFMT and the nerve transfer restore biceps function if donors are available, we aim to maximize elbow flexion.

**TABLE 4. Postoperative EMG Data**

| n           | Time After Surgery (mo) | Reinnervation of Gracilis | Reinnervation of Biceps |
|-------------|-------------------------|---------------------------|-------------------------|
| <b>SFMT</b> |                         |                           |                         |
| 3           | 18                      | Yes                       | Yes                     |
| 4           | 17                      | Yes                       | Yes                     |
| 5           | 9                       | Yes                       | Yes                     |
| 6           | NA                      | NA                        | NA                      |
| 7           | 22                      | Yes                       | Yes                     |
| 9           | 25                      | Yes                       | Not applicable          |
| 11          | 14                      | Yes                       | Yes                     |
| 12          | 19                      | Yes                       | Yes                     |
| <b>DFMT</b> |                         |                           |                         |
| 1           | NA                      | NA                        | NA                      |
| 2           | 28                      | Yes                       | Yes                     |
| 8           | 27                      | Yes                       | Not applicable          |
| 10          | 14                      | Yes                       | Not applicable          |

NA, not available.

We found an extremely high incidence of preganglionic injuries in our series of patients, with all children having either partial or complete (C5–T1) nerve root avulsions. This is consistent with other reports,<sup>2,3,17–19</sup> with other differences in pediatric patients compared with adults reported, such as a faster recovery time, higher incidence of associated skeletal injuries, and minimal deafferentation pain. Although DFMT provides the most complete reconstruction of elbow flexion and prehension, it may not be appropriate for all patients owing to lack of sufficient donor nerves or unwillingness of the patient and family to undergo 2 major surgeries and prolonged rehabilitation. The DFMT is also not an option for patients presenting more than 6 months after injury. In Doi et al's description of the DFMT,<sup>5,6</sup> reinnervation of the triceps brachii as an antagonist of the elbow flexor is essential to ensure that patients can stabilize the elbow joint and position the hand in space while extending the fingers. In injuries more than 6 months old, nerve transfers are unlikely to restore triceps function owing to motor end plate degeneration, which makes the use of DFMT for restoration of prehension impractical.<sup>4,16</sup> Thus, whereas we offer DFMT to all suitable patients whose injury is less than 6 months old, available nerve donors and willingness to undergo 2 major surgeries within a 6-week period of time, we more often perform a single gracilis transfer, with priority focused on restoration of elbow flexion, especially in patients presenting more than 6 months from injury.

Our results are encouraging, with 11 out of 12 patients achieving M3 or greater elbow flexion. When looking at DFMT and SFMT as separate cohorts, all patients (n = 4) achieved M3 or better elbow flexion in the DFMT cohort, and 7 out of 8 patients achieved M3 or better elbow flexion in the SFMT cohort. Eight out of 12 patients had nerve transfers to the MCN, which might have confounded analysis of results. Results of adjunctive nerve transfers were less promising. As a referral center, most often the rehabilitation after surgery is performed by a local center, often by therapists unfamiliar with these injuries and rehabilitation nuances. The importance of postoperative rehabilitation in outcomes following FFMT is emphasized by Doi et al<sup>6</sup> and others, with failure of adherence to a strict rehabilitation regime possibly having compromised outcomes in some patients. Limited shoulder abduction in many of our patients may have been due in part to insufficient postoperative rehabilitation. In patients with poor outcomes following nerve transfers to the shoulder, our practice is now to perform tendon transfers secondarily to augment shoulder external rotation and spare use of the SAN.<sup>20</sup>

Unlike the study of 3 patients by Hattori et al,<sup>9</sup> we found a high incidence of elbow joint contracture after surgery. This complication developed in 2 out of the 3 patients between 4 and 12 years old and likely reflects discrepant growth between the transferred muscle and the humerus. As a result, we carefully consider the use of FFMTs in children in this age group unless there are no other reconstructive options and then only after prolonged discussion with the family about the likely occurrence of elbow flexion contracture and need for subsequent procedures such as biceps tendon lengthening or interposition autograft tendon. Biceps tendon lengthening was performed in one patient in this series with elbow flexion contracture. Secondary reconstructive procedures such as tenodesis and arthrodesis, which interfere with skeletal growth, are also best deferred until skeletal maturity.

We recognize the limitations inherent to retrospective studies as well as our small cohort of patients. Other limitations include a shorter follow-up period of 14 months in 2 patients, as well as some missing outcomes data. Unfortunately, because most patients come from out of state, many are unable to return for follow-up review and continuing care, complicating data collection in BPI research.

## REFERENCES

1. Bishop AT. Functioning free-muscle transfer for brachial plexus injury. *Hand Clin.* 2005;21(1):91–102.

2. Dumontier C, Gilbert A. Traumatic brachial plexus palsy in children. *Ann Chir Main Memb Super*. 1990;9(5):351–357.
3. El-Gammal TA, El-Sayed A, Kotb MM. Surgical treatment of brachial plexus traction injuries in children, excluding obstetric palsy. *Microsurgery*. 2003;23(1):14–17.
4. Barrie KA, Steinmann SP, Shin AY, Spinner RJ, Bishop AT. Gracilis free muscle transfer for restoration of function after complete brachial plexus avulsion. *Neurosurg Focus*. 2004;16(5):E8.
5. Doi K, Kuwata N, Muramatsu K, Hattori Y, Kawai S. Double muscle transfer for upper extremity reconstruction following complete avulsion of the brachial plexus. *Hand Clin*. 1999;15(4):757–767.
6. Doi K, Muramatsu K, Hattori Y, et al. Restoration of prehension with the double free muscle technique following complete avulsion of the brachial plexus. Indications and long-term results. *J Bone Joint Surg Am*. 2000;82(5):652–666.
7. Beliaising AS, Doi K, Hattori Y. Bilateral elbow flexion reconstruction with functioning free muscle transfer for obstetric brachial plexus palsy. *J Hand Surg Br*. 2002;27(5):484–486.
8. Chuang DC, Hattori Y, Ma HS, Chen HC. The reconstructive strategy for improving elbow function in late obstetric brachial plexus palsy. *Plast Reconstr Surg*. 2002;109(1):116–126.
9. Hattori Y, Doi K, Ikeda K, Pagsaligan JM, Watanabe M. Restoration of prehension using double free muscle technique after complete avulsion of brachial plexus in children: a report of three cases. *J Hand Surg Am*. 2005;30(4):812–819.
10. Boome R. Traumatic brachial plexus surgery in children. In: Gupta A, Kay SPJ, Schecker LR, eds. *The Growing Hand: Diagnosis Management of the Upper Extremity in Children*. London: Mosby; 2000:653–657.
11. Pritchett JW. Growth plate activity in the upper extremity. *Clin Orthop Relat Res*. 1991;268:235–242.
12. Pritchett JW. Growth and predictions of growth in the upper extremity. *J Bone Joint Surg Am*. 1988;70(4):520–525.
13. Mendel JR, Florence J. Manual muscle testing. *Muscle Nerve*. 1990;13(Suppl):S16–S20.
14. Carlsen BT, Bishop AT, Shin AY. Late reconstruction of brachial plexus injury. *Neurosurg Clin N Am*. 2009;20(1):51–64.
15. Giuffre JL, Bishop AT, Spinner RJ, Kircher MF, Shin AY. Wrist, first carpometacarpal joint, and thumb interphalangeal joint arthodesis in patients with brachial plexus injuries. *J Hand Surg Am*. 2012;37(12):257–263.e1.
16. Shin AY, Spinner RJ, Steinmann SP, Bishop AT. Adult traumatic brachial plexus injuries. *J Am Acad Orthop Surg*. 2005;13(6):382–396.
17. Gilbert A, Pivato G, Kheiralla T. Long-term results of primary repair of brachial plexus lesions in children. *Microsurgery*. 2006;26(2):334–342.
18. Goubier JN, Teboul F, Papadogeorgou E. Nerve transfers in children with traumatic partial brachial plexus injuries. *Microsurgery*. 2008;28(1):117–120.
19. Miller JH, Garber ST, McCormick DE, et al. Oberlin transfer and partial radial to axillary nerve neurotization to repair an explosive traumatic injury to the brachial plexus in a child: case report. *Childs Nerv Syst*. 2013;29(11):2106–2109.
20. Elhassan B, Bishop A, Shin A, Spinner R. Shoulder tendon transfer options for adult patients with brachial plexus injury. *J Hand Surg Am*. 2010;35(7):1211–1219.